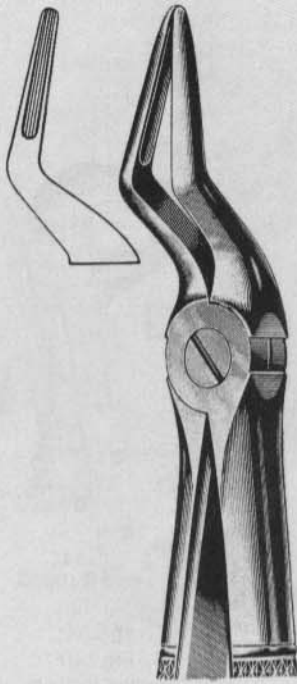
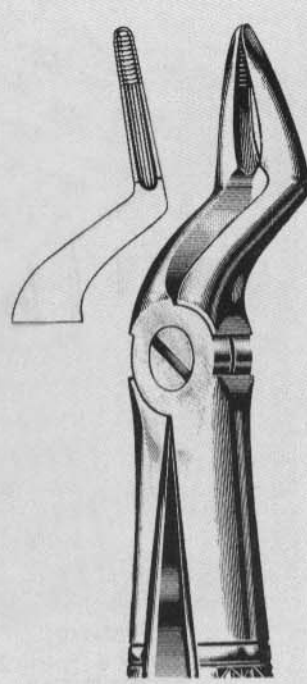




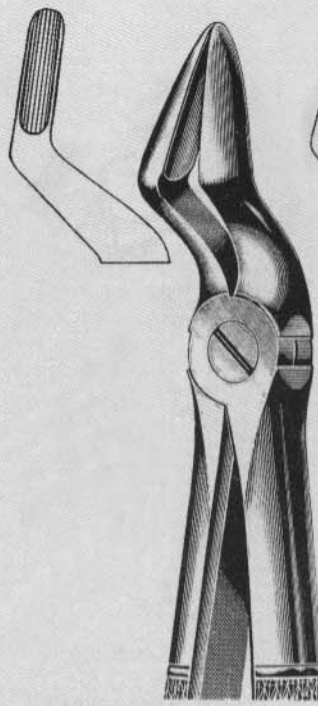
Extracting Forceps (English Pattern)



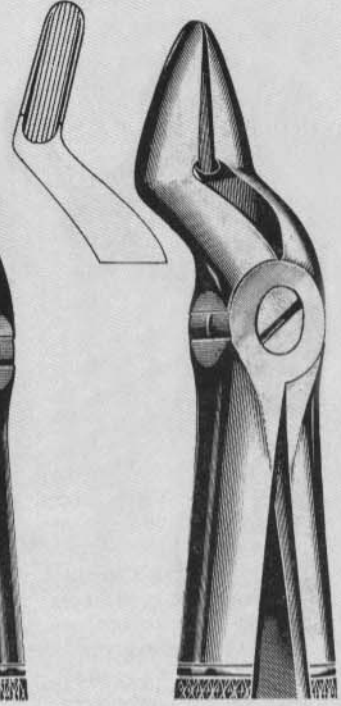
130
Fig. 51A
Upper roots
narrow beak



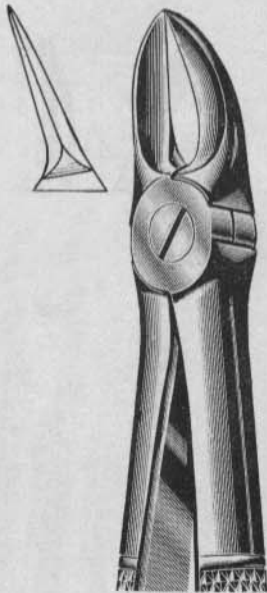
131
Fig. 51C
Upper roots



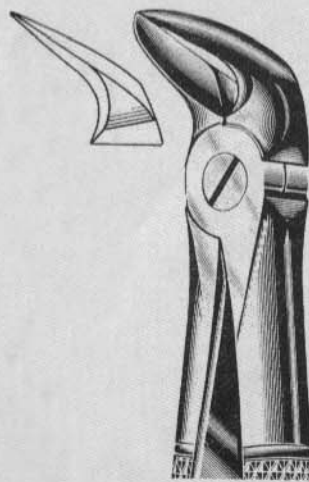
132
Fig. 52
Upper roots & canines
with wider beak



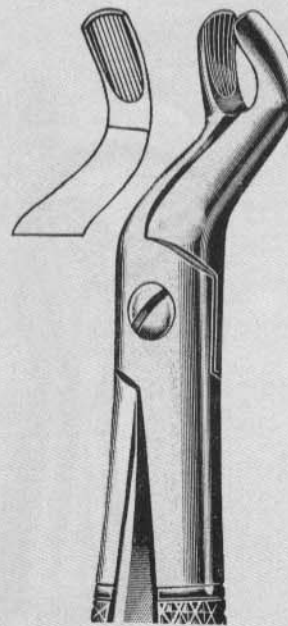
133
Fig. 52A
Upper teeth &
resection



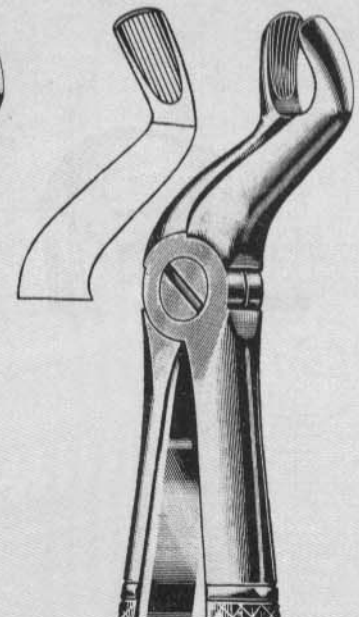
134
Fig. 55
Separating upper
molars roots



135
Fig. 56
Separating lower
molars roots



136
Fig. 67
Upper wisdoms



137
Fig. 67A
Upper wisdoms